

PREPARATION DESIGN PRINCIPLES

A. Mancuso DDS, MAGD



Millennium Aesthetics

Preparation Design

- **General Considerations**
- **Special Situations**



General Considerations

- Empress Preparation
- Golden Rule of Preparation
- Before You Get Started
- Universal Principles

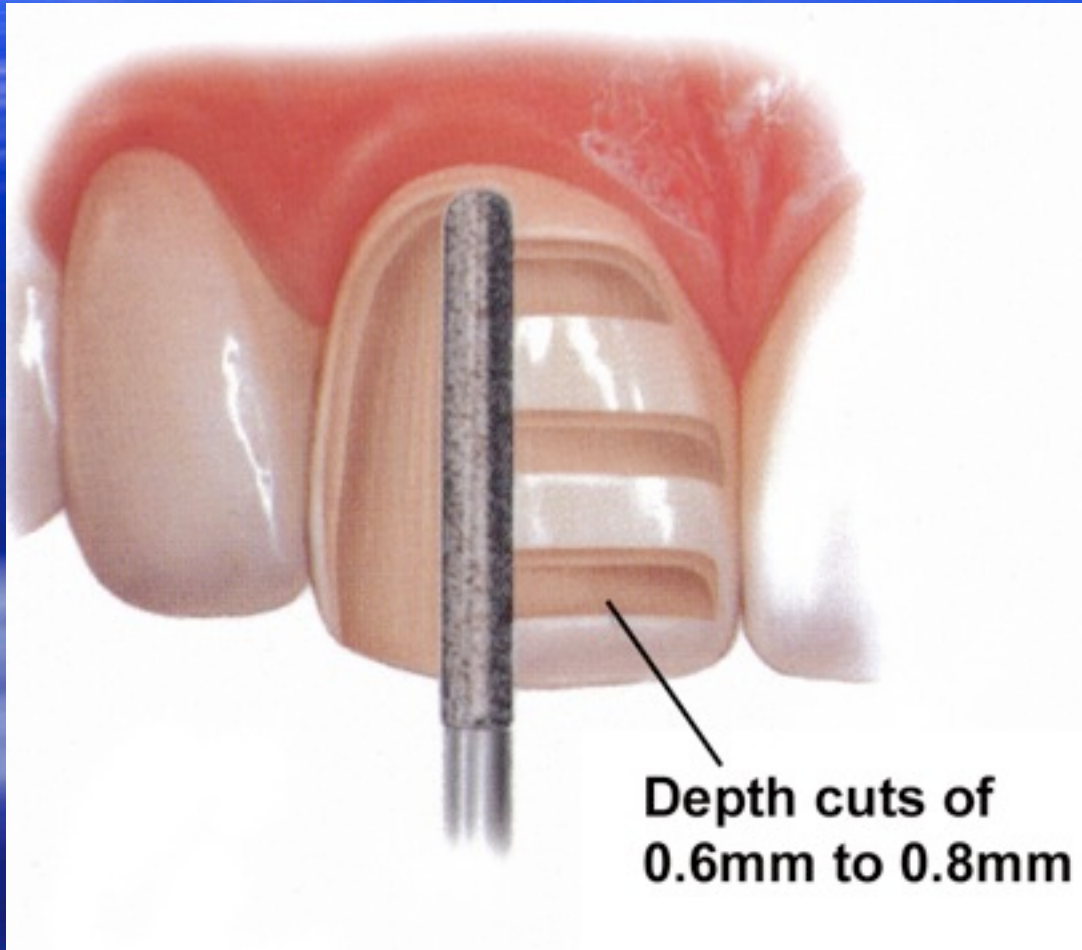


General Considerations

Empress Preparation

Uniform Facial Preparation

A medium grit, round-ended, diamond bur is used to remove a uniform thickness of facial enamel by joining the depth-cut grooves.

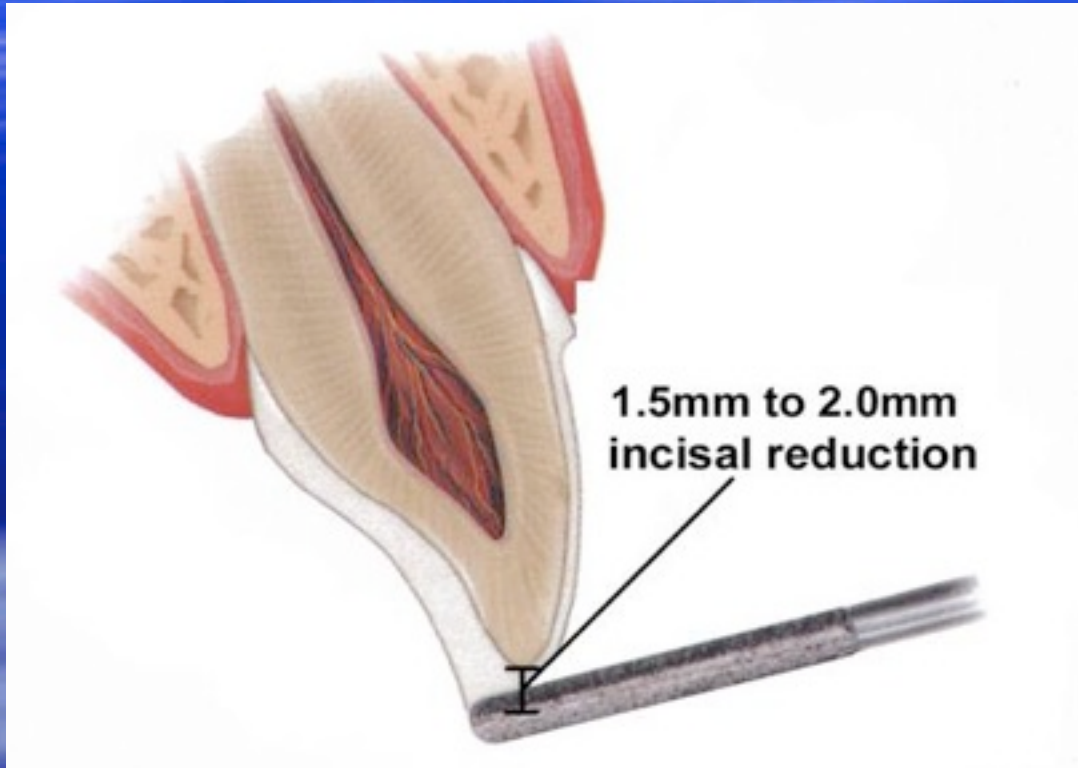


Millennium Aesthetics



General Considerations

Empress Preparation

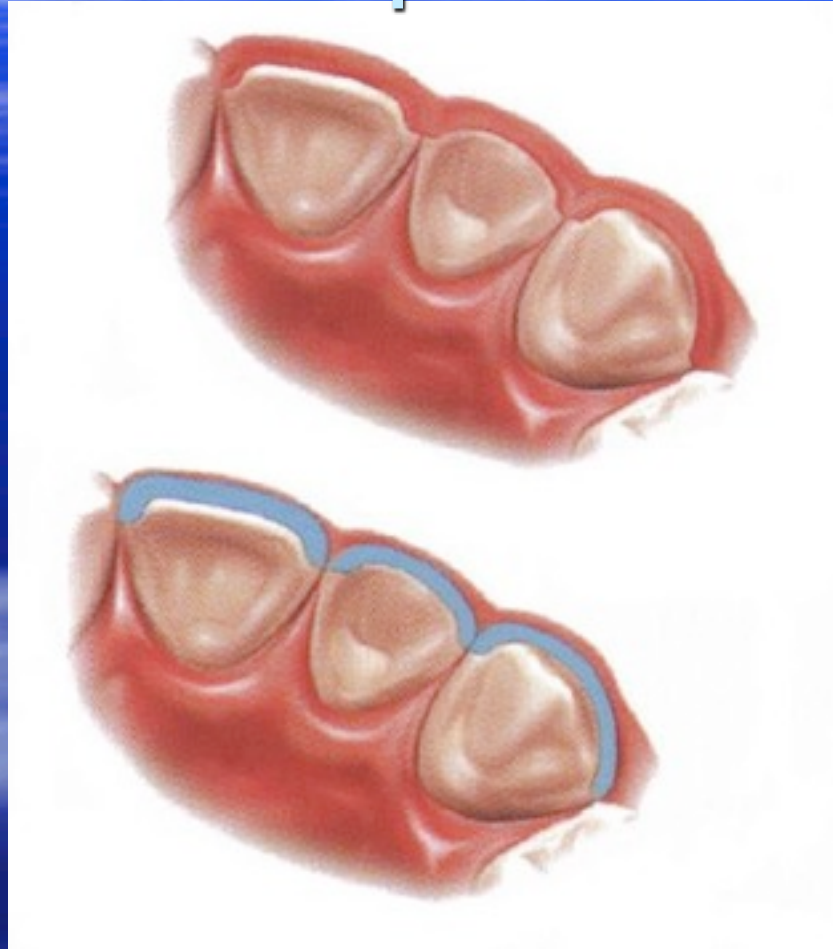


Incisal Preparation

The diamond bur is angled to bevel back the incisal edge.

General Considerations

Empress Preparation



Chamfer Margins

Correct preparation of the chamfer margins interproximally allows the appropriate bulk of porcelain.

Millennium Aesthetics

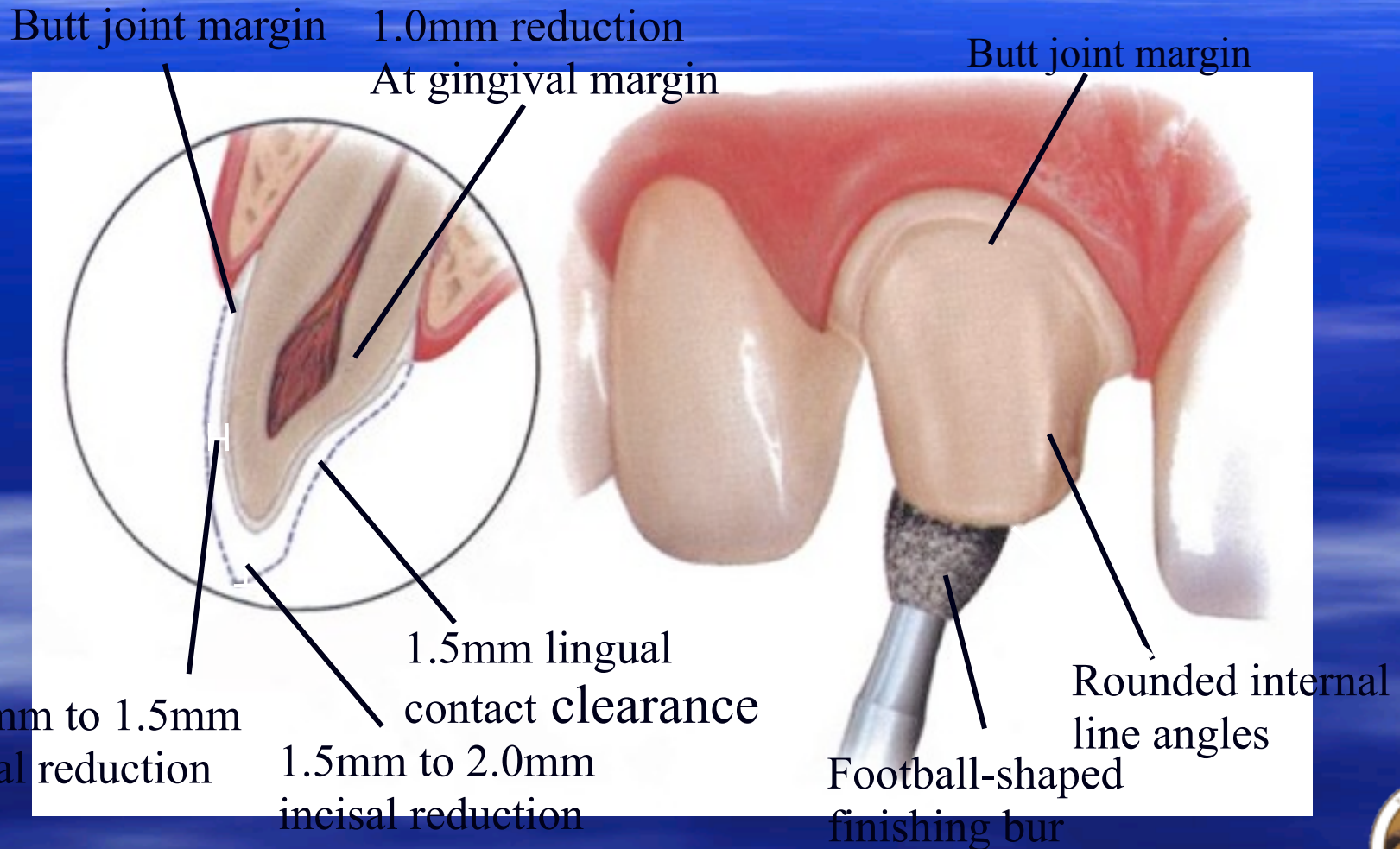


General

Considerations

Empress Preparation

Anterior Crown Preparation



Millennium Aesthetics



General Considerations

Golden Rule of Prep Design
**“Prep the tooth where you want it to
be, not where it is.**

It doesn't matter where it is.”



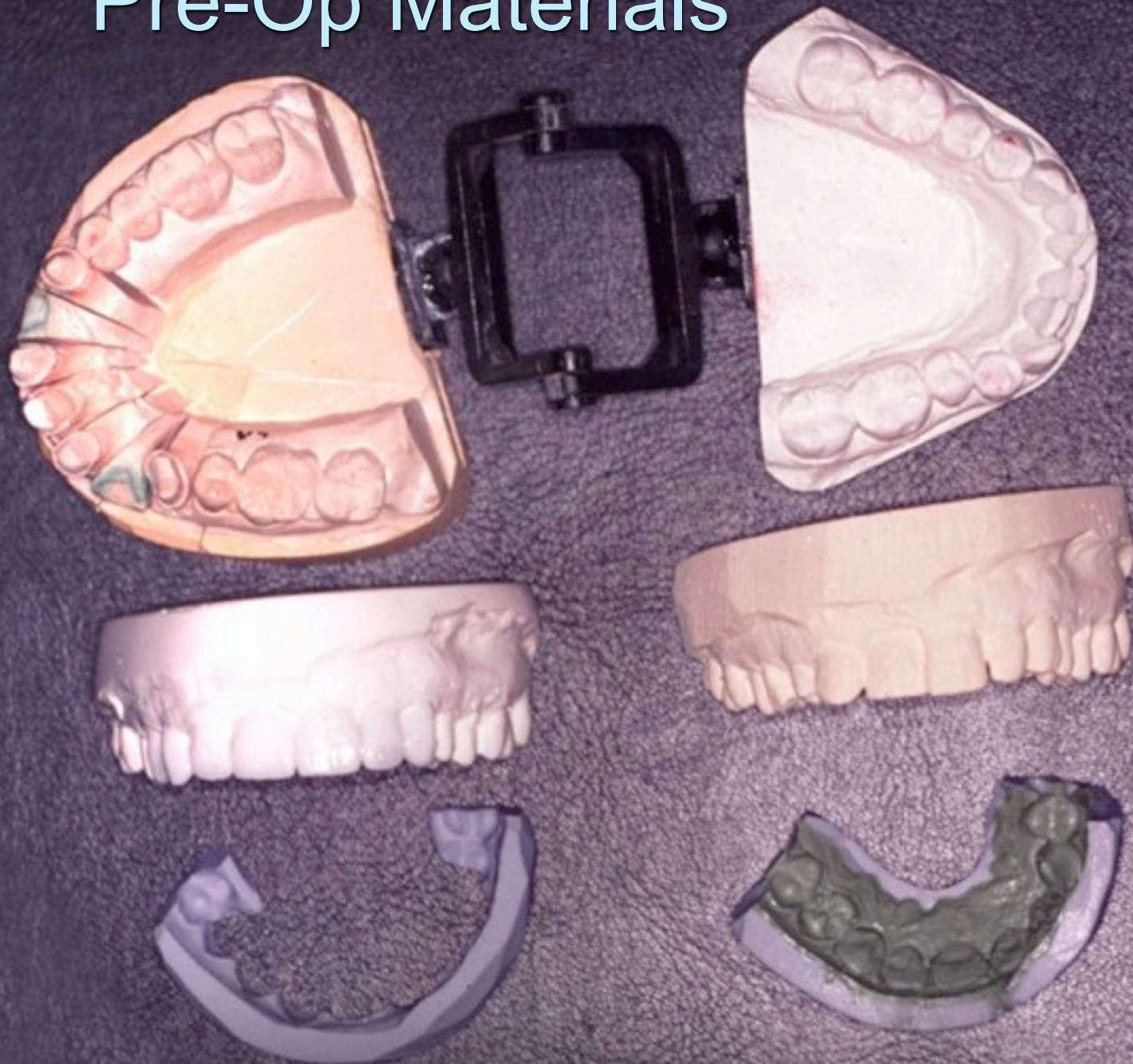
General Considerations

Before You Get Started

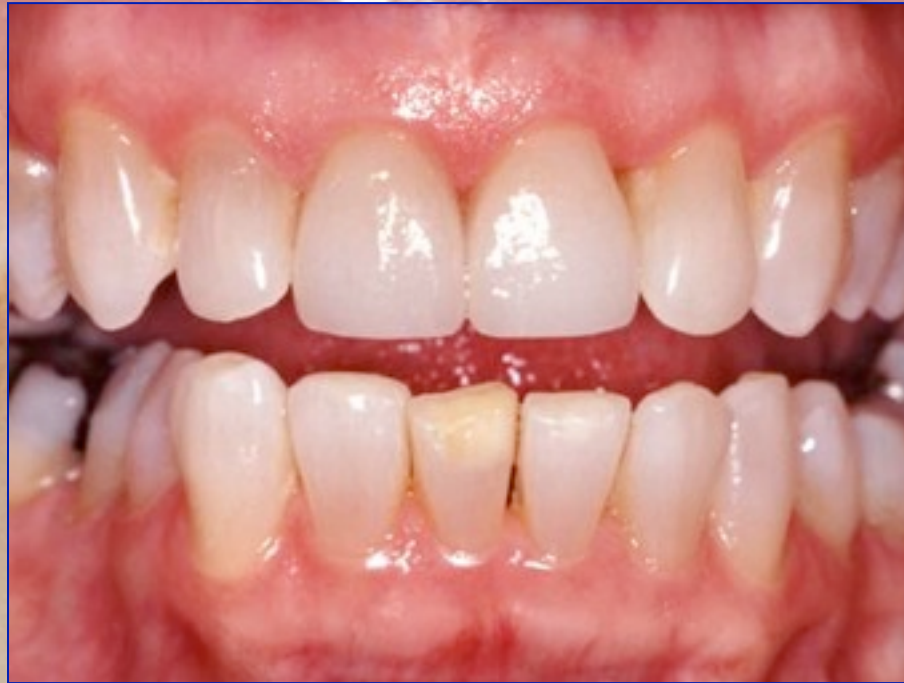- Pre-Op Materials
 - Study Models
 - Photos
 - Wax-up with Silicone Index
 - Preparation Index
- Soft Tissue Recontouring
- Arch Form Recontouring
(Including Opposing Arch)
- Depth Cuts



Pre-Op Materials




Soft Tissue Recontouring



Arch Form Recontouring

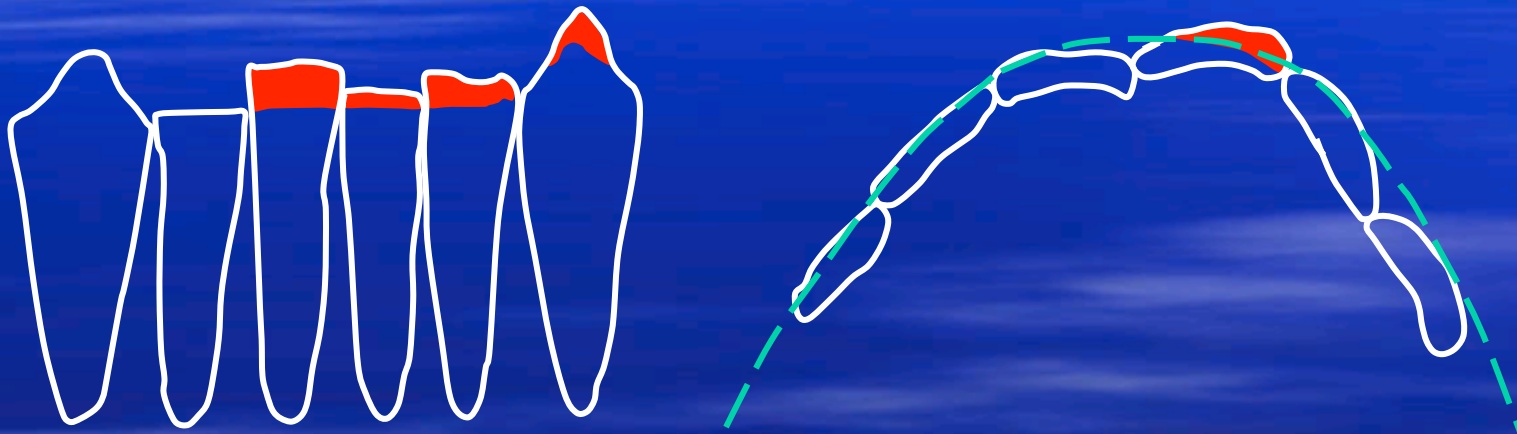
Prepped Arch



Millennium Aesthetics



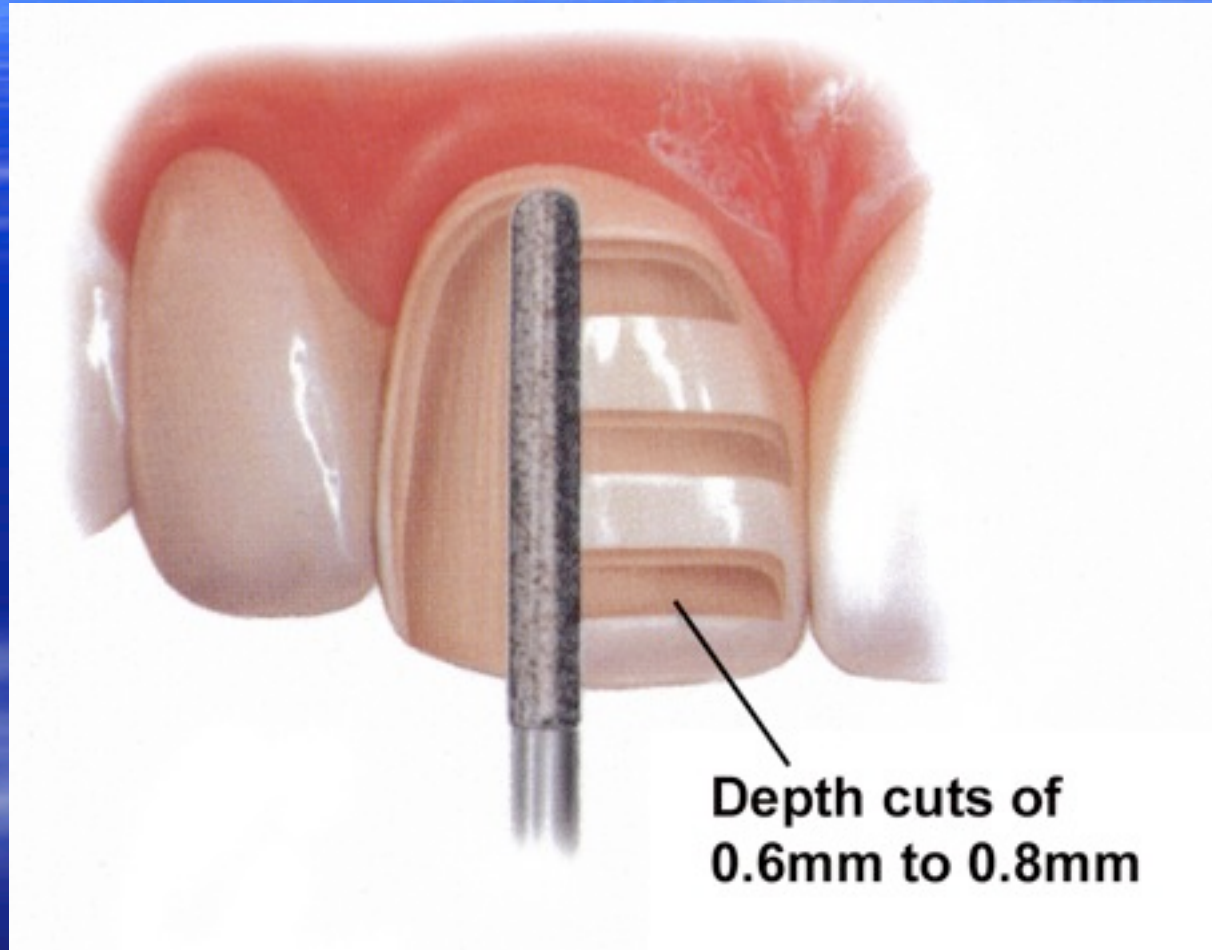
Arch Form Recontouring Opposing Arch



Millennium Aesthetics



Depth Cut



Millennium Aesthetics

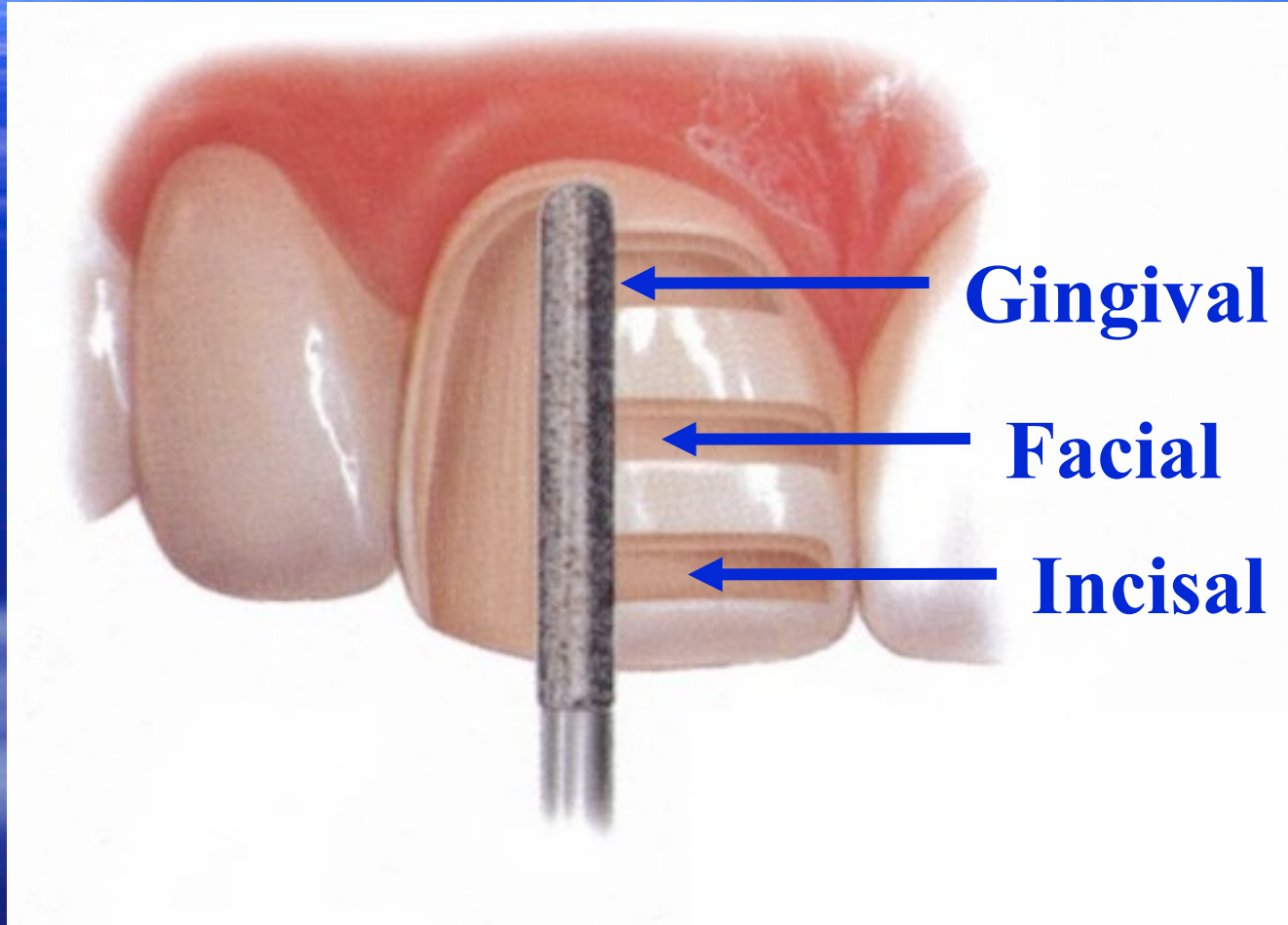


Universal Principles

- 3 Plane Facial Reduction
- Incisal Reduction (1.5mm – 2 mm)
- Interproximal Reduction
 - Elbow or Slice
- Lingual Finish Line
 - Depends on Occlusion and/or Previous Restorations
- 4 Views: Mesial, Distal, Incisal, Facial



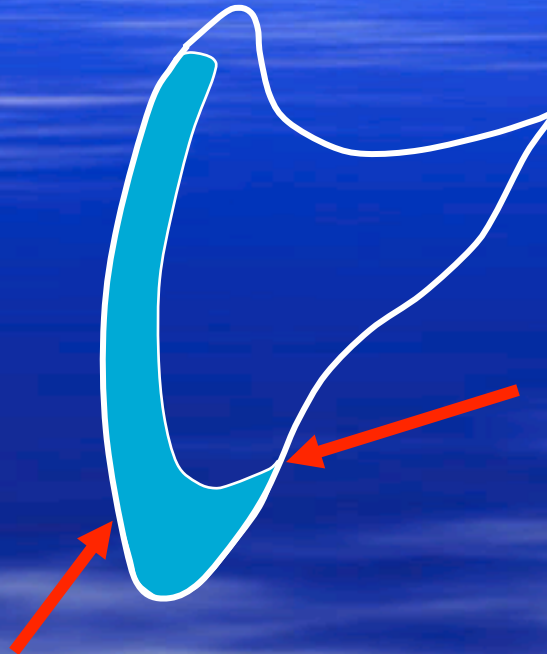
3 Plane Facial Reduction



Millennium Aesthetics



Incisal Reduction



Lingual Bevel (approx.
 45°)

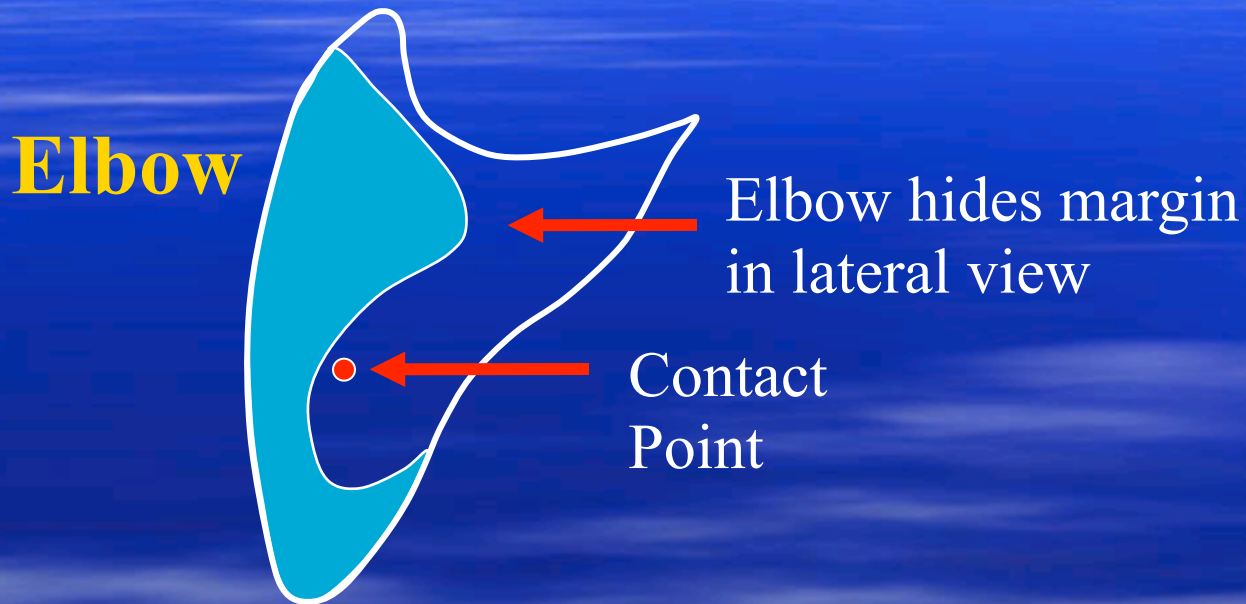
This is actually a butt
joint to the lab tech.

1.5mm to 2.0mm
Incisal Reduction

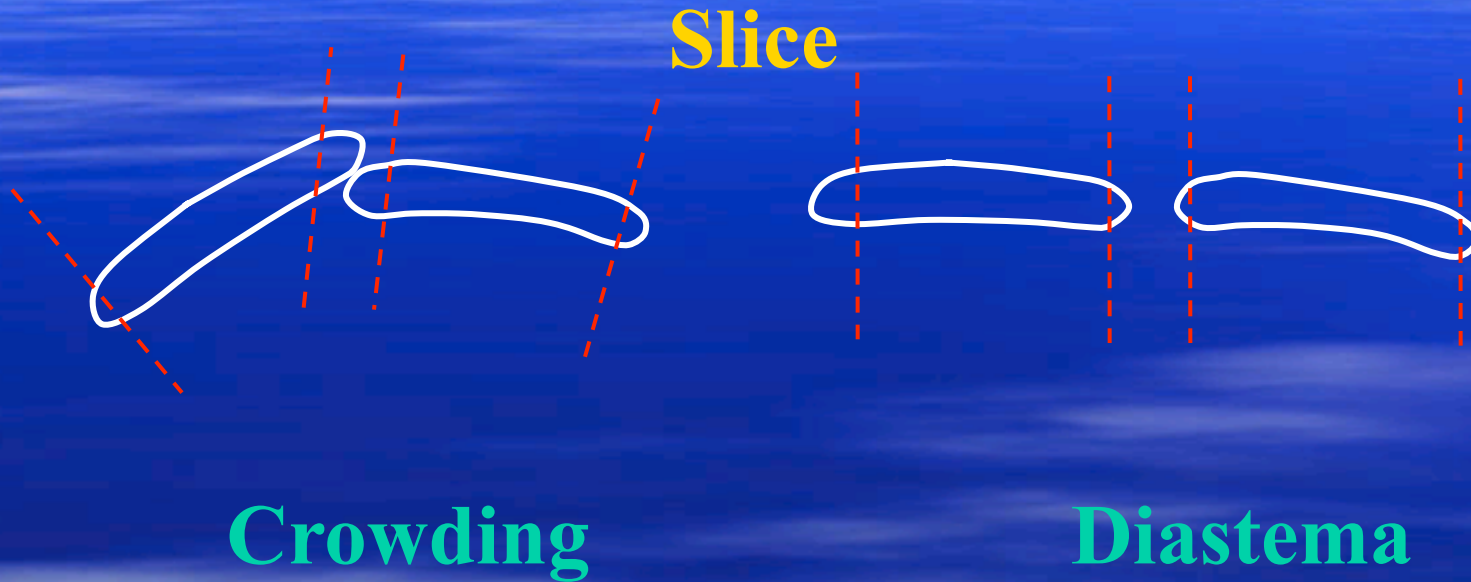
Millennium Aesthetics



Interproximal Reduction



Interproximal Reduction

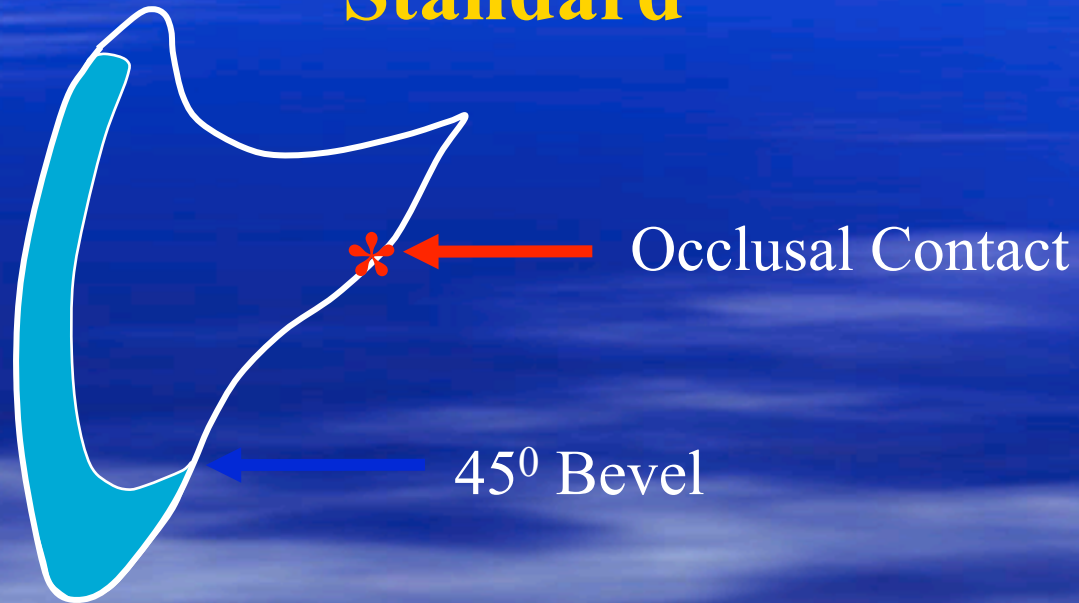


Slicing allows lab to alter width of teeth.



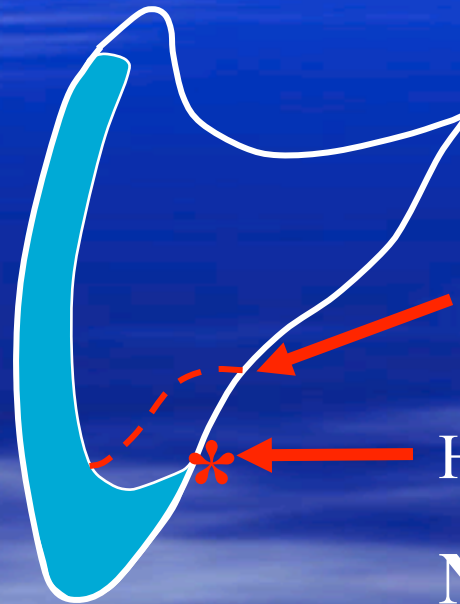
Lingual Finish Line

Standard



Lingual Finish Line

Occlusal Considerations

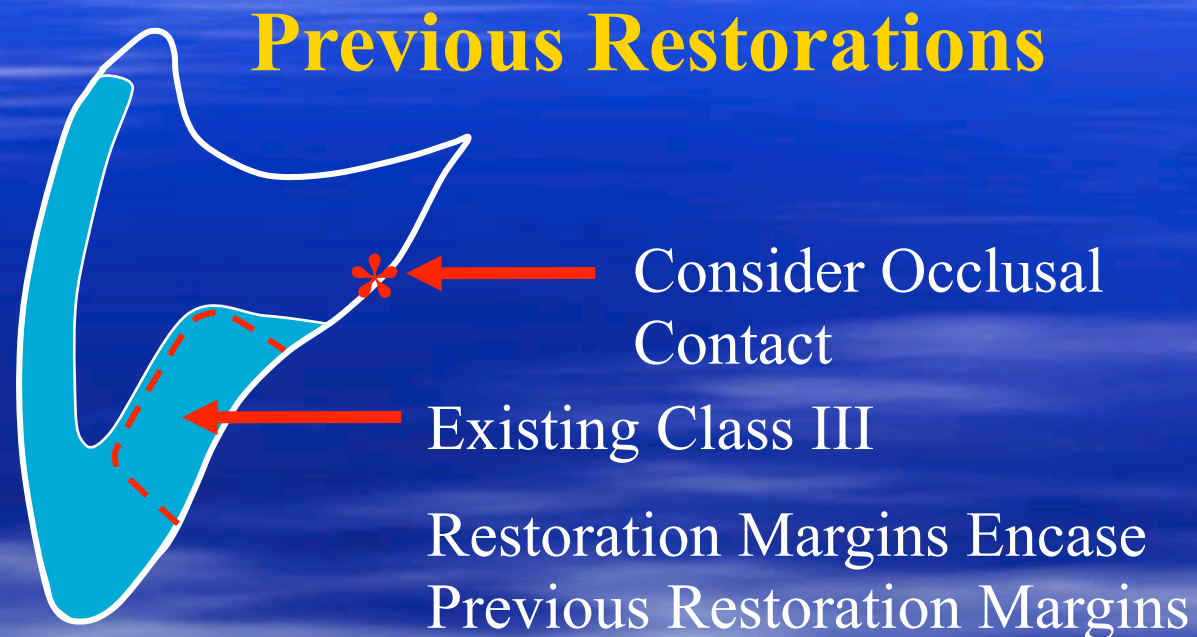

New Finish Line to
Incorporate Contact
(Chamfer)

High Occlusal Contact

Never have finish line
on contact point

Lingual Finish Line



Always remove existing restorations. May replace to block out under cuts, but all veneer margins on sound tooth structure.

Millennium Aesthetics



4 Views

- Mesial
- Distal
- Incisal
- Facial

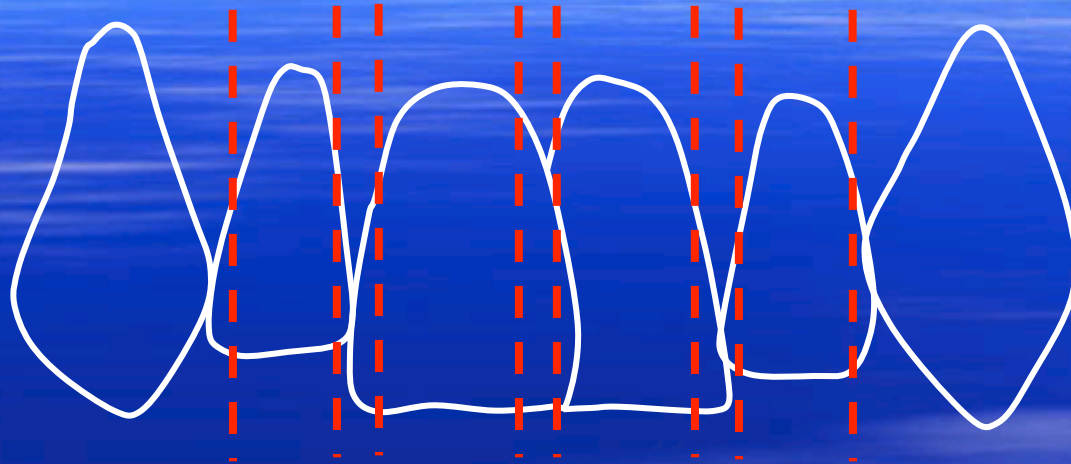


Special Situations

- Crowding- Instant Orthodontics
- Space Closure- Gaps
- Lingual/Facial Version- Arch Form
- Midline Discrepancies
- Premolar Designs



Crowding



Consideration

1. Proper W/L ratio of centrals and golden proportion
 - Wax-up vital
2. Slice Preps. # of teeth involved depends on space requirement.
 - If in doubt – slice
3. Severe crowding may require root recontouring

Millennium Aesthetics




michelle

Millennium Aesthetics

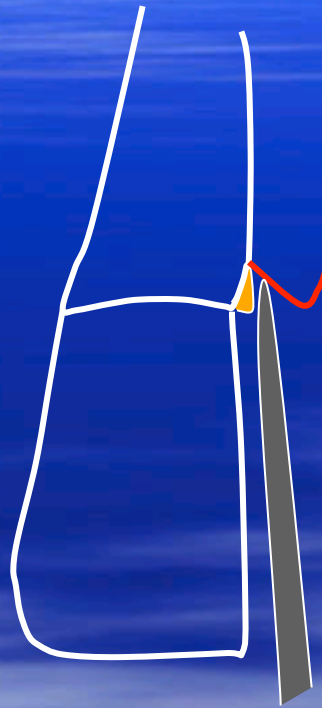

Wednesday, November 10, 2010

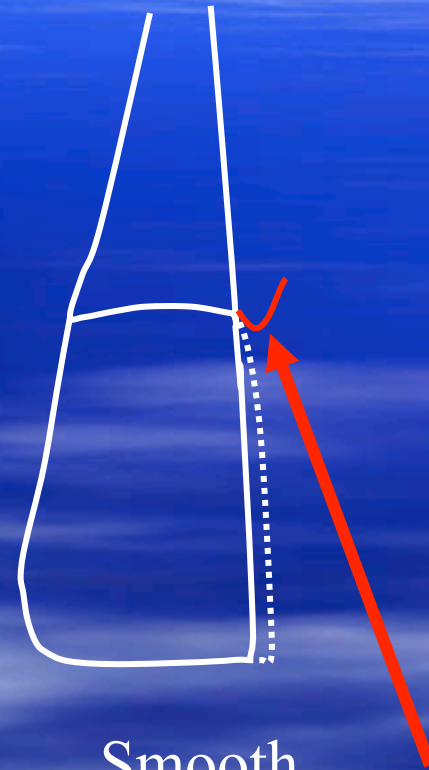Root Recontouring



Proximal Slice



Narrow
Diamond
Recontours

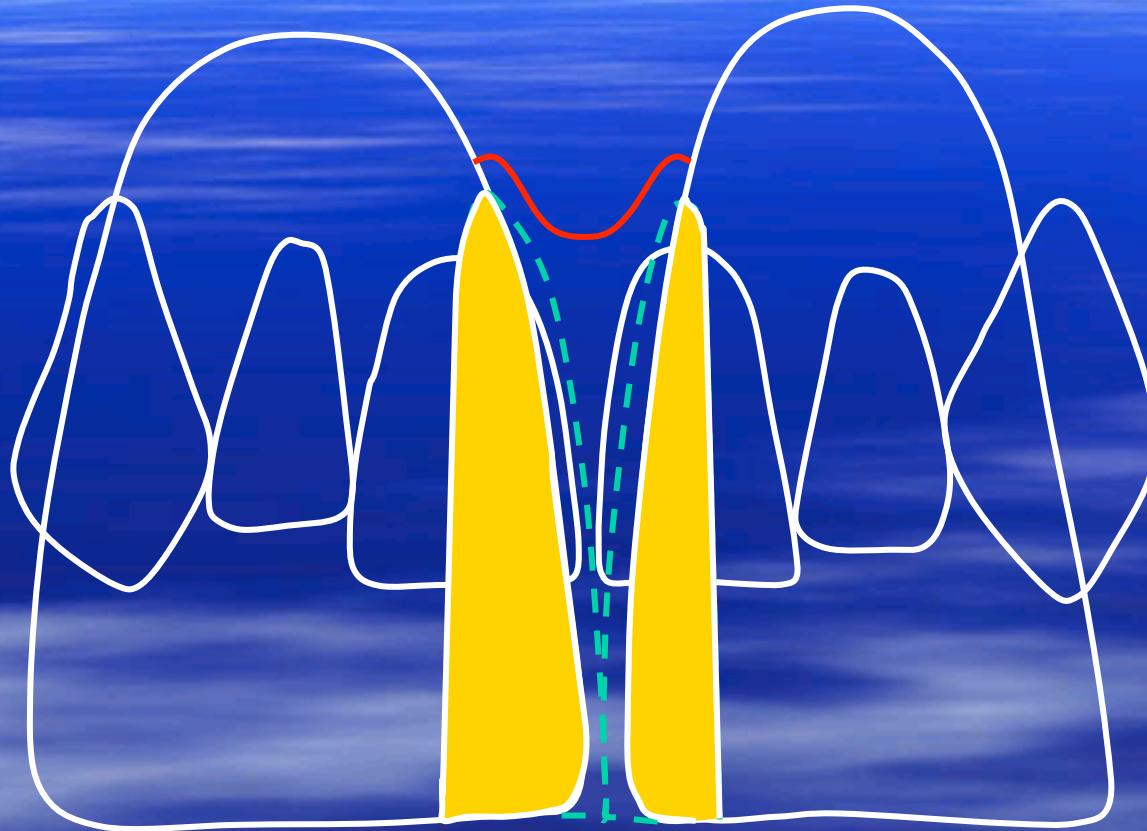


Smooth
Transition from
Root to
Restoration

Millennium Aesthetics



Space Closure



Subgingival slice prep allows lab to obtain proper emergence profile interproximally and not create a ledge here.

Close up

Millennium Aesthetics



GAPS-Cases

Millennium Aesthetics



Lingual/Facial Version

Facial Version

**Original
Position**



**Desired
Position**


Millennium Aesthetics



Lingual/Facial Version

Step 1: Idealize Arch

Bulk Removal →

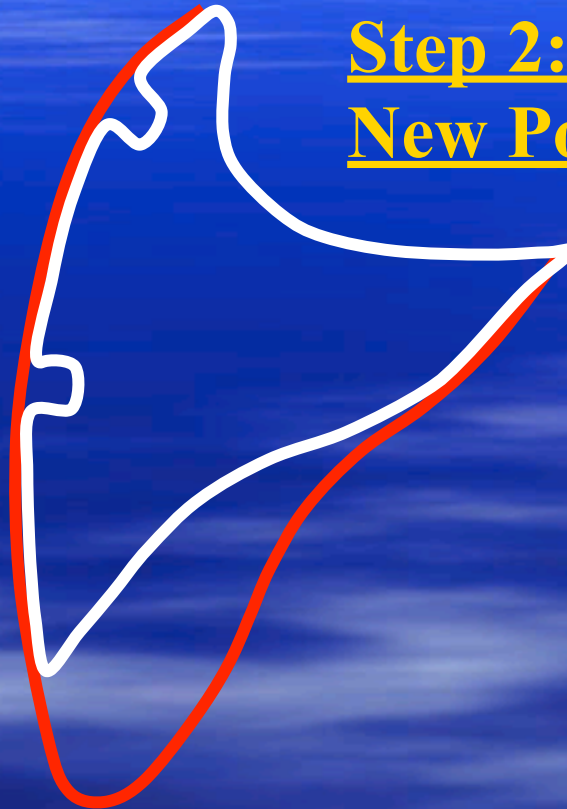

Millennium Aesthetics



Lingual/Facial Version

Step 2: Depth Cuts at
New Position




Millennium Aesthetics



Lingual/Facial Version

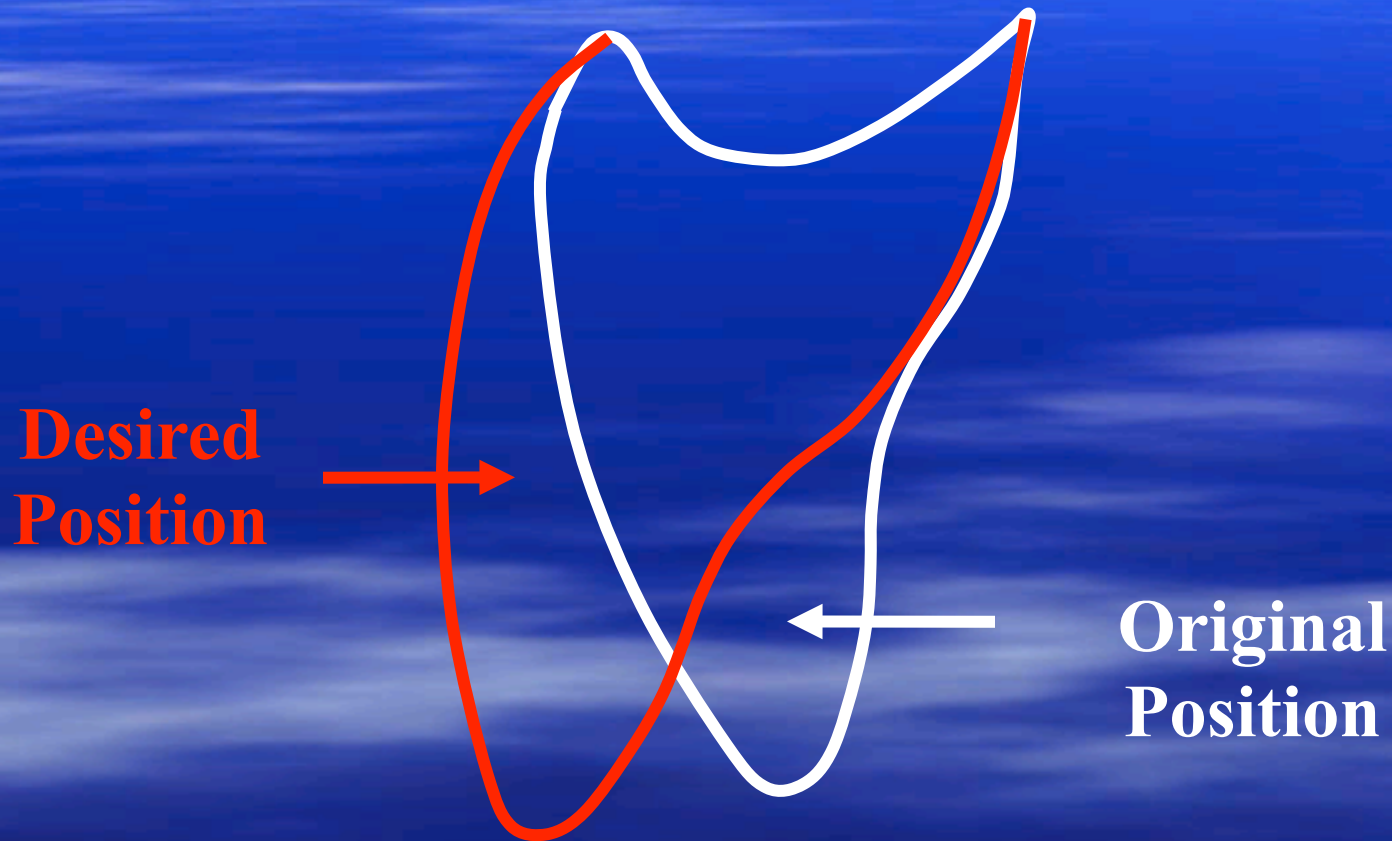
Step 3: Final Prep



Only lingual
reduction is
margin
establishment

Lingual/Facial Version

Lingual Version

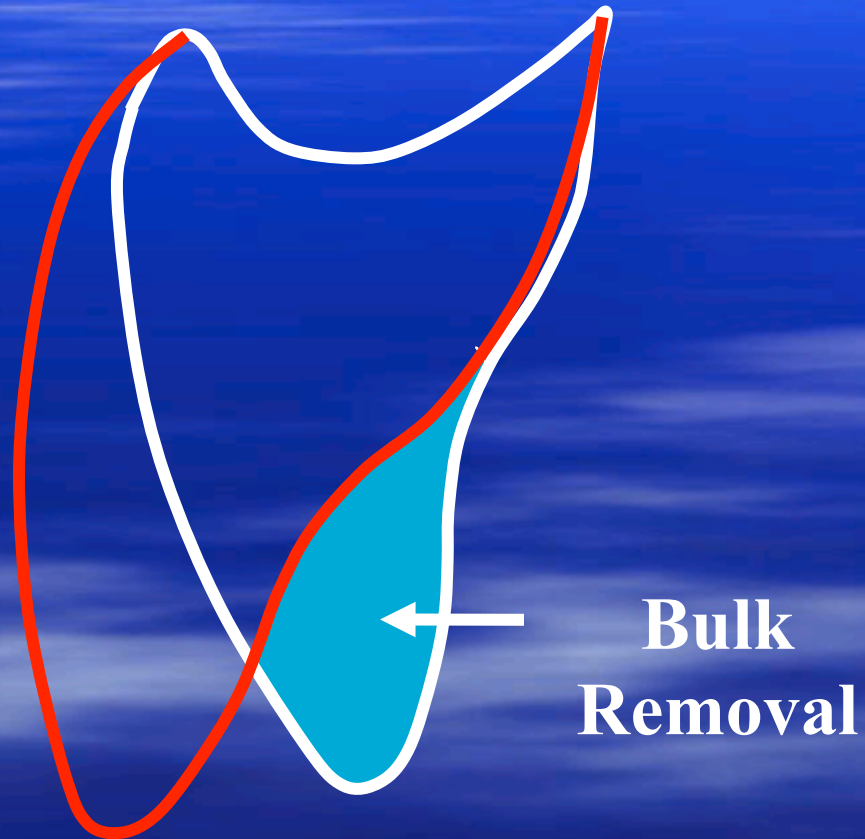


Millennium Aesthetics



Lingual/Facial Version

Step 1: Idealize Arch



Millennium Aesthetics



Lingual/Facial Version

Step 2: Depth Cuts at New Position




Millennium Aesthetics



Lingual/Facial Version

Step 3: Final Prep

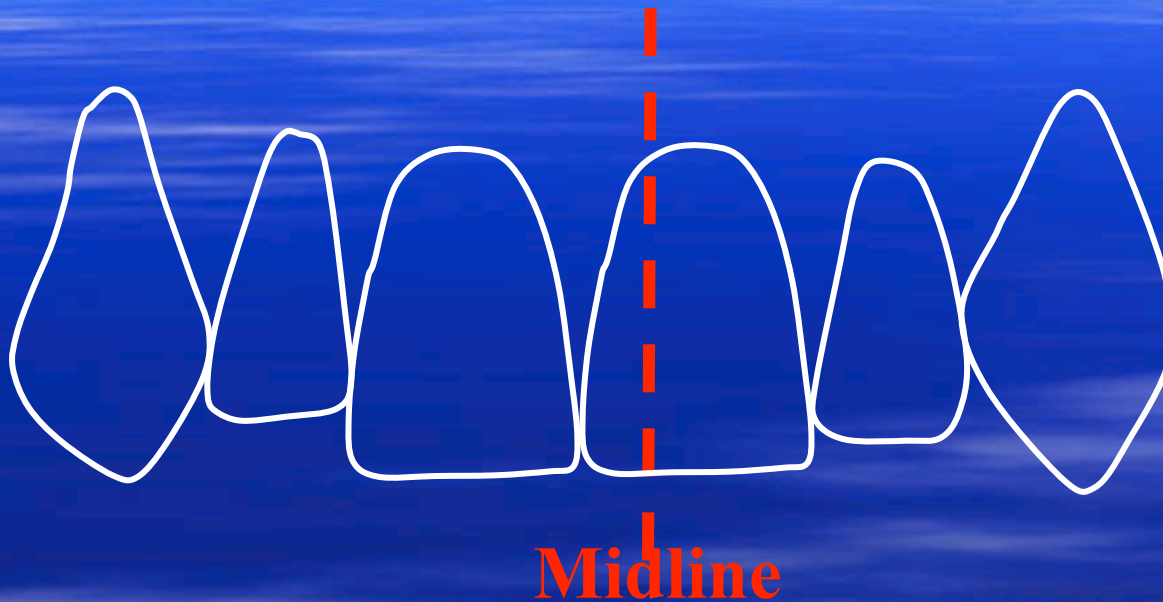
**Only facial
reduction is
margin
establishment**



Millennium Aesthetics



Midline Discrepancies

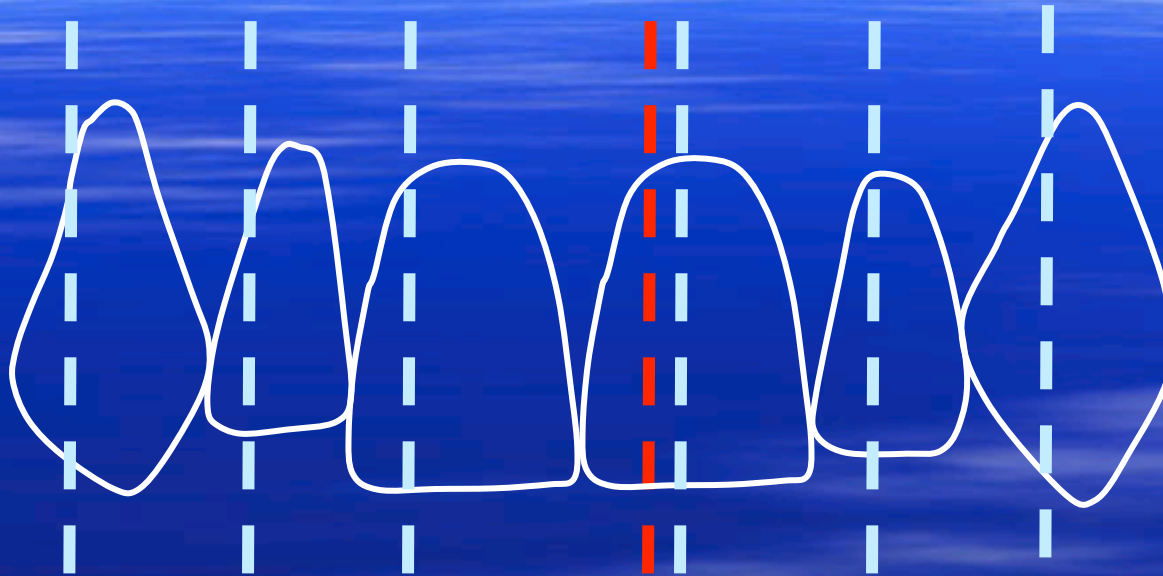


Dental Midline needs to be moved to the left so teeth left of midline need aggressive **Mesial Reduction** while teeth right of the midline need aggressive **Distal Reduction**.

Opposite holds true for midline movement to right.



Midline Discrepancies



Midline

Preps are subgingival slice preps +/- Root Recontouring

Millennium Aesthetics



Premolar Designs

A. Step Prep



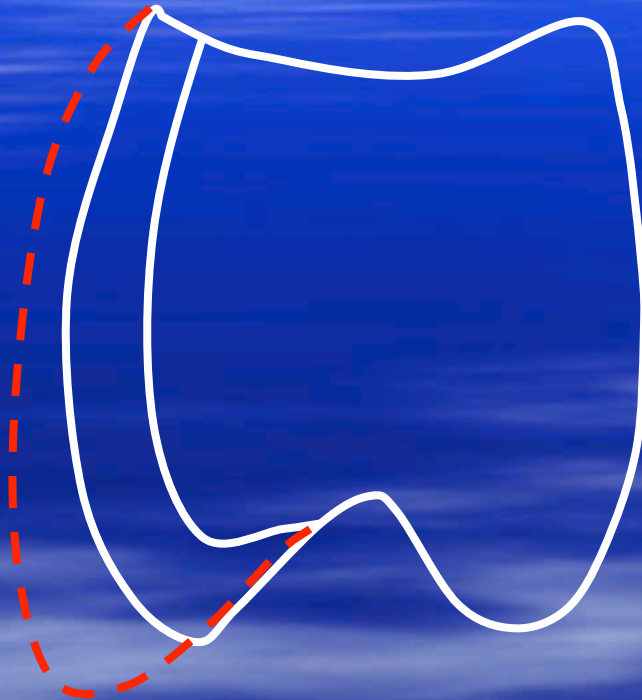
Usually only used for shade change.

Millennium Aesthetics



Premolar Designs

B. Wrap Prep



**Usually for shade change
as well as for developing buccal corridor.**

Millennium Aesthetics

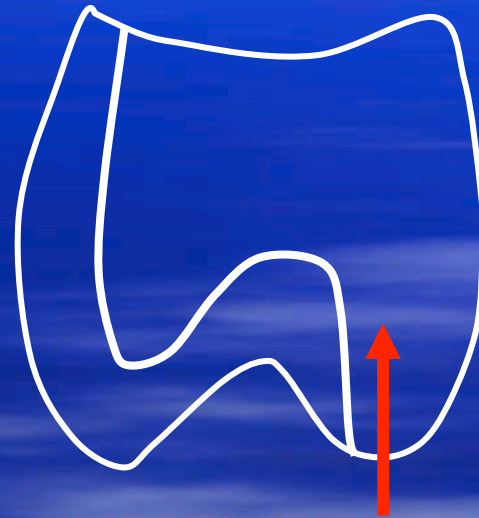

Premolar Designs

C. Onlay/Veneer Prep

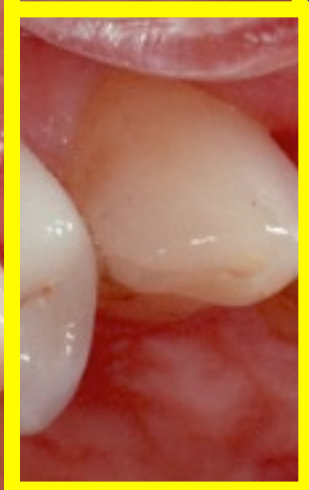
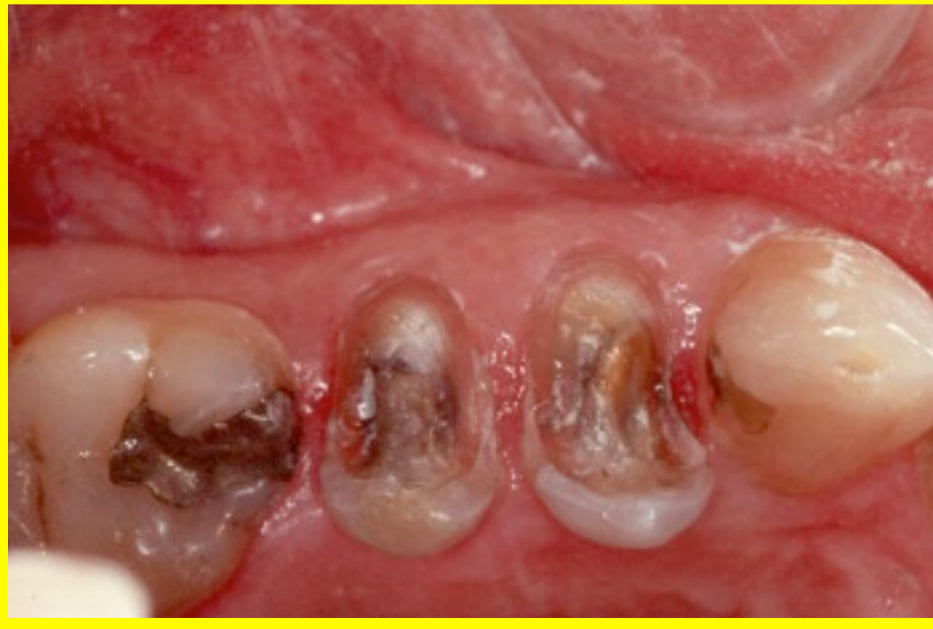
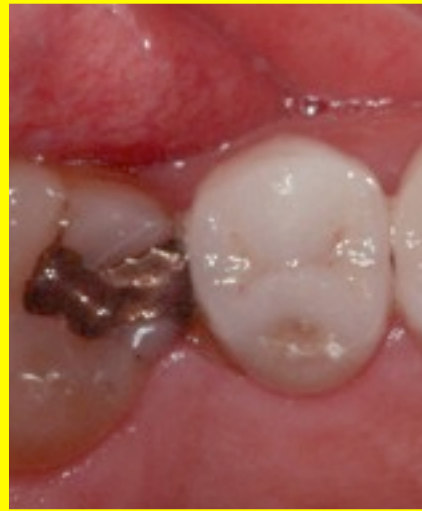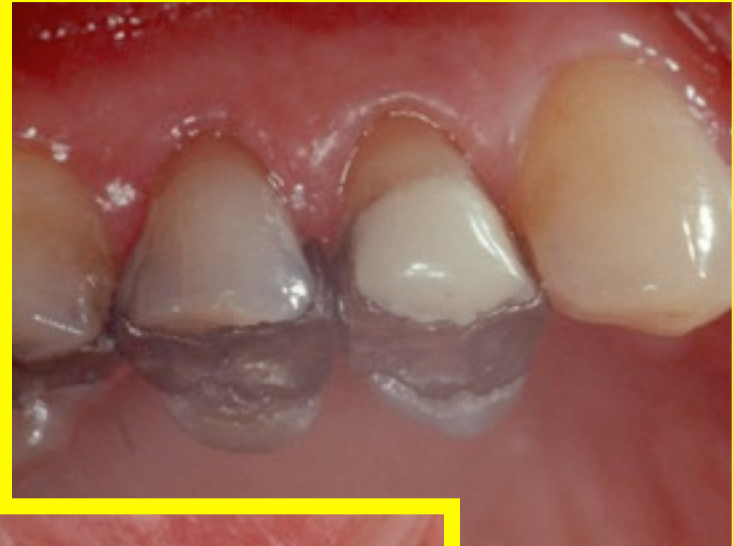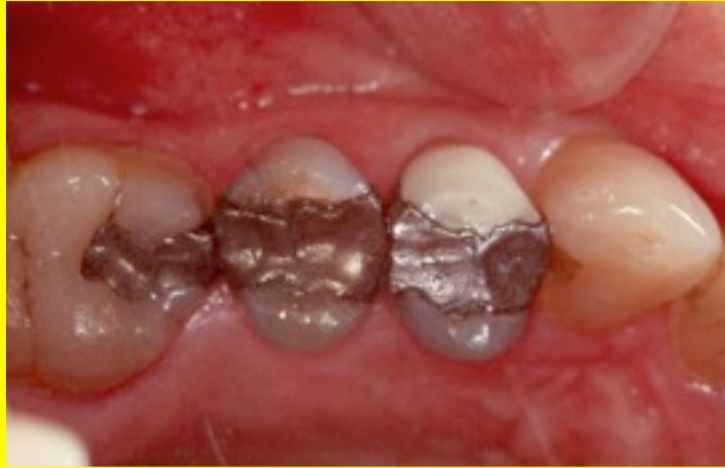**MOD
amalgam**



**Untouched
Lingual Cusp**

EMPRESS Restorations





Millennium Aesthetics



- Golden Rule of Preparation
“Prep the tooth where you want it to be, not where it is. It doesn’t matter where it is.”

